

**A Short Case:
Suicidal Attempt by a University Student
Dr WL Yip**

CASE 1

- × F/21yo
- × University student
- × Suicidal attempt 15hrs before
 - + 52x 20mg citalopram
 - + 18x 25mg promethazine
- × Sleepy at home
- × Limb twitching, aborted with valium
- × To ICU

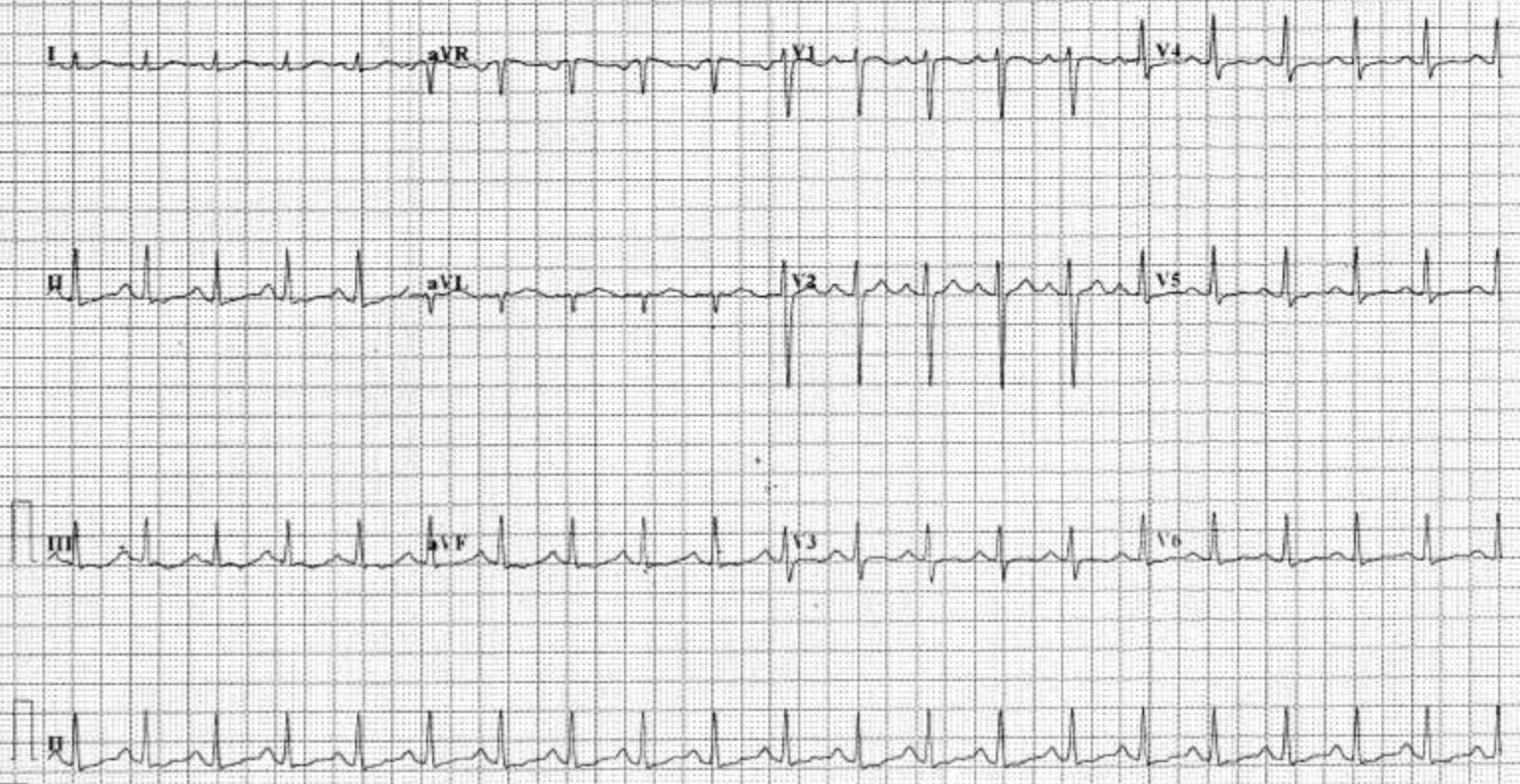
ID: AE131115243
Name:
Age:

HR : 122 BPM
P Dur : 111 ms
PR int : 159 ms
QRS Dur : 94 ms
QT/QTc int : 308/440 ms
P/QRS/T axis : 67/75/-13
RV5/SV1 amp : 0.851/1.004 mV
RV5+SV1 amp : 1.855 mV
RV6/SV2 amp : 0.830/1.662 mV

Diagnosis Information:
812: Sinus Tachycardia
611: Low T Wave(V5)

(C)

Unconfirmed Report.



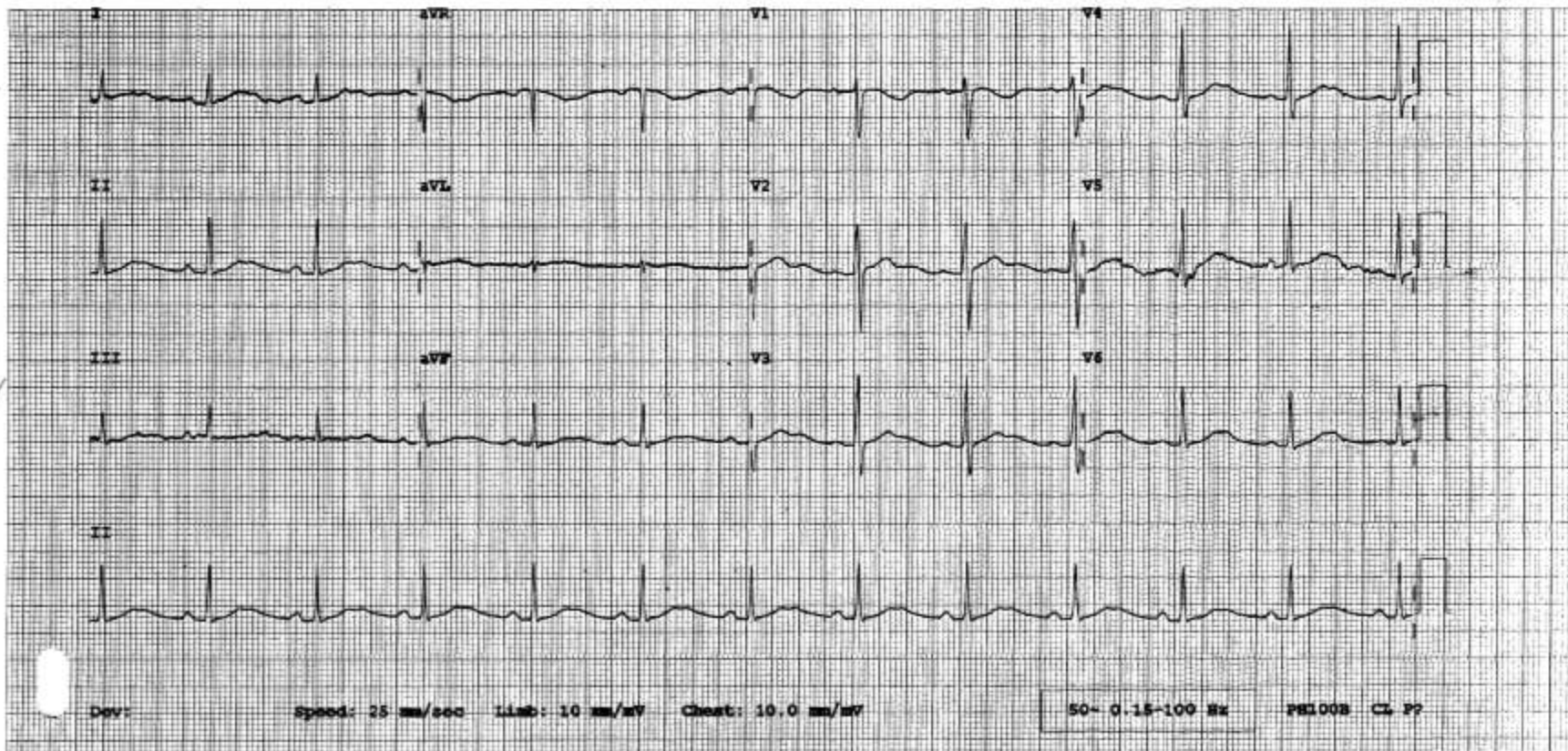
Rate 74 . Age not entered, assumed to be 50 years old for purpose of ECG interpretation
 RR 811 . Sinus rhythm.....normal P axis, V-rate 50- 99
 PR 160 . Prolonged QT interval.....QTc >500ms
 QRS 87
 QT 531
 QTcB 590
 QTcF 589
 --AXIS--
 P 56
 QRS 56
 T 41

6

8

- ABNORMAL ECG -

Unconfirmed Diagnosis



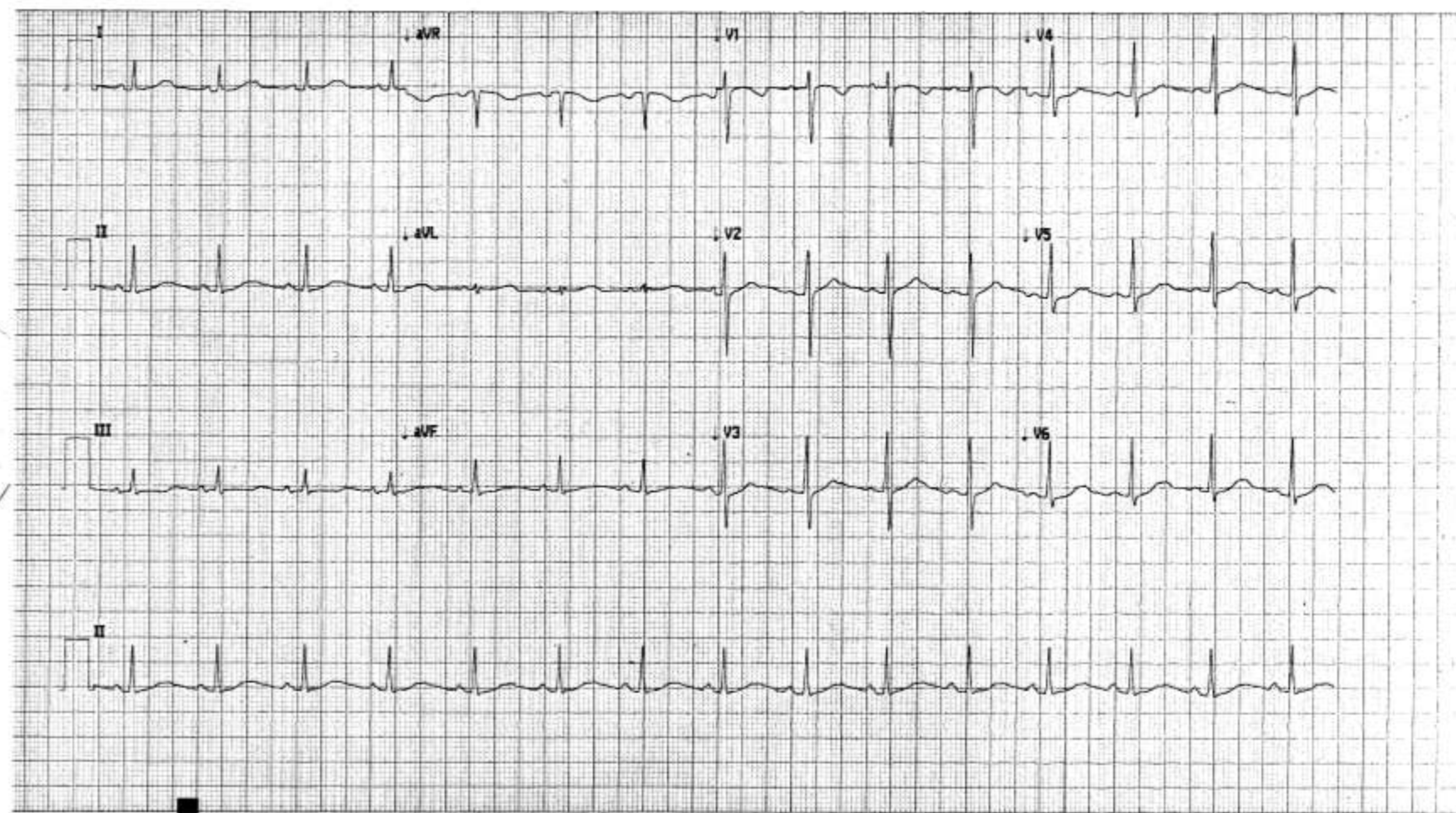
HN13119276Y,

14-Nov-2013 15:37:04

Vent rate: 89 BPM
PR int: 143 ms
QRS dur: 85 ms
QT/QTc: 301/348 ms
P-R-T axes: 47 52 29

SINUS RHYTHM
NONSPECIFIC T WAVE ABNORMALITY
SHORT QT INTERVAL
ABNORMAL ECG
UNCONFIRMED REPORT

10



-
- ✘ Prolonged QTc up to 590ms
 - ✘ MgSO₄
 - ✘ Returned to 490ms the next day